

94 1
3.75

THE AMERICAN JOURNAL OF CANCER

Editor

FRANCIS CARTER WOOD

THE INSTITUTE OF CANCER RESEARCH
OF
Columbia University

Volume XXIV

The Official Organ of
The American Association for Cancer Research
and
The American Association for the Study of
Neoplastic Diseases

NINETEEN HUNDRED AND THIRTY-FIVE

Copyright, 1935, by the Institute of Cancer Research
of Columbia University

COLLEGE OF PHARMACY
OF
PHILADELPHIA

PULMONARY ASBESTOSIS III: CARCINOMA OF LUNG IN ASBESTO-SILICOSIS

KENNETH M. LYNCH, M.D., AND W. ATMAR SMITH, M.D.

(From the Departments of Pathology and Medicine, Medical College of the State of South Carolina)

Primary carcinoma of the lung has attained a position of major interest in malignant neoplastic disease, through at least a more common recognition, if not more frequent occurrence, within recent years. Likewise asbestosis has assumed a rank of considerable importance in industrial medicine.

Workers in the mines of the Erz Mountains, on both the Bohemian and the Saxon sides, have suffered heavily for some centuries from pulmonary disease now recognized as carcinoma and well known as Schneeberg and Jáchymov (Joachimstal) lung cancer.

Pirchan and Šild (1), in a report upon a series of these cases, state that "there were only moderate degrees of anthracosis," and they are not inclined to attach any particular importance to the degree of pneumoconiosis as a cause of the cancer, but consider that "the question may be somewhat different with regard to the quality of the foreign substance deposited in the lung." Chemical analysis in one of their cases revealed "only calcium, magnesium, aluminum, silicic acid, chlorides, and phosphates; no trace of arsenic, bismuth, cobalt, nickel, or uranium was found." They lay suspicion, as others have done, upon radium emanation and upon arsenic, both factors being encountered in the Schneeberg and Jáchymov mines.

Rostoski, Saupe and Schmorl (2) found severe "anthracosis" in Schneeberg miners the subjects of lung cancer and are inclined to attribute the causation of the cancer to the anthracosis, while Simpson (3) states that pulmonary cancer is a rare complication of silicosis in South African miners. Schulte (4) has reported lung cancer in pneumoconiosis among coal miners, and Saupe (5) has recorded two cases in arsenic miners. There appears to be no previous report of its occurrence in asbestos miners or mill workers, although the record of autopsy examinations of cases of asbestosis is not large.

As worthy of record in the interest of both diseases, as well as their possible relationship, the following case of pulmonary asbestosis with associated carcinoma of the lung is reported.

CASE REPORT

A white man, fifty-seven years of age at the time of his death, first came under observation at the Shirras Dispensary of the Roper Hospital on Jan. 10, 1934, at which time he appeared very old, weak, and

emaciated
"stomach
breath.

History
no time w
he had no
but excep
from wor
the three
pains oc
days. F
toms unt
ing the r
The pai
It seeme
quite wo
work at
medical
aggrav
veloped
blood r

The
Occ
occur
in a c
doors
did no
work
a job
to ho
pende
ginni
of the
Abou
very
wint
settl
air f
side
last
stea
tom

two
yea
in
to

emaciated. His chief complaints were pains in the right side of the "stomach," right side of the back and shoulder, and shortness of breath.

History: Prior to 1931 the patient's health was good and practically no time was lost from work as a result of illness, although for five years he had noticed some shortness of breath. He had had influenza in 1918, but except for that had always been well. In 1931 he lost three days from work on account of sharp pains in his back, extending down over the three lower ribs. Nine months later intermittent sharp shooting pains occurred involving his right shoulder. These lasted about ten days. Except for the shortness of breath, there were no further symptoms until Nov. 7, 1933, when there were renewed attacks of pain involving the right shoulder, axilla, and the three lower ribs on the same side. The pain occurred about every hour and lasted about thirty minutes. It seemed to be more severe during the night. The patient also became quite weak and seemed to lose weight. He was now compelled to quit work and seek medical aid. During November and December, under medical care, he grew weaker and lost more weight, his dyspnea was aggravated, and a cough, productive of wiry, white mucoid sputum developed. On Jan. 8, during a spell of coughing, he expectorated fresh blood mixed with mucoid material.

The family history was not significant.

Occupational History: The first exposure to a dusty atmosphere occurred when the patient was about sixteen, when he began to work in a cotton mill as a weaver. He first worked in a place with open doors and windows, and later a humidifying system was installed; he did not consider the atmosphere excessively dust laden. He continued work as a weaver in various cotton mills until 1913, when he obtained a job as a weaver at an asbestos factory, which he held until just prior to hospital admission. During times when his work there was suspended he did odd jobs, with apparently no occupational hazards. Beginning in 1913, he worked in an extremely dusty atmosphere, in spite of the fact that windows and doors were kept open as much as possible. About 1923 a humidifying system was installed, but this he considered very inefficient, though it improved the atmosphere somewhat. In winter the heating system kept the air in the plant too dry to allow settling of dusty particles. In summer, when all doors were kept open, air from the forced draft from the "preparation room," emptying outside the plant, entered the room in which the patient worked. The last five or six months of his employment he was at "wet work" instead of dry weaving, reducing the exposure to dust. He was accustomed to work overtime, since he was paid by the yard.

This man, then, worked as a cotton mill weaver for approximately twenty-two years and as an asbestos mill weaver for some twenty-one years, which may account for certain features of silicosis in the lungs, in addition to those of asbestosis.

Course: Throughout his stay in the hospital the patient continued to complain of persistent pain along the right costal border and right

side of the abdomen. The cough, with expectoration of a large quantity of mucopurulent sputum, continued and became more aggravated. There was anorexia, with progressive loss of weight and strength. For the first three weeks after admission there was an irregular afternoon elevation of temperature. In the latter weeks of the illness fever of remittent type was constantly present (99° - 101°), rising on the day of death to 104° . The pulse rate ranged between 90 and 100. The respiratory rate was constantly above normal and on the slightest exertion there was dyspnea.

Examination: In general appearance the patient looked much older than fifty-seven. He appeared exhausted and was extremely weak and

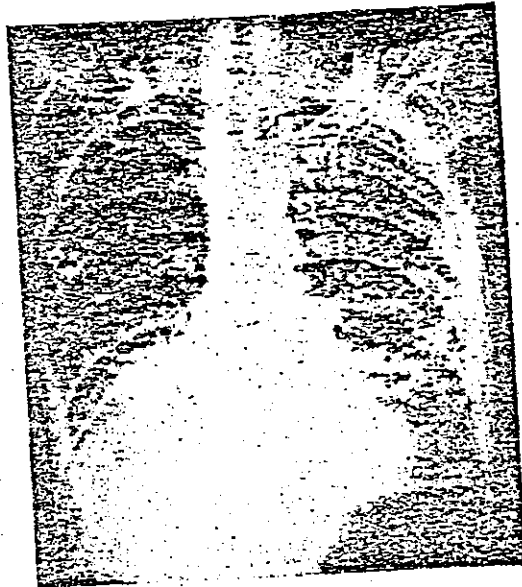


FIG. 1. ROENTGENOGRAM SHOWING PULMONARY ASBESTO-SILICOSIS AND CARCINOMA OF LOWER RIGHT LOBE

emaciated. The finger nails and toe nails were clubbed and somewhat cyanotic.

The bony thorax was of the emphysematous type. Expansion was equal but poor. Dullness was present over the bases of both lungs, being more marked on the right. The upper levels were resonant. Breath sounds were suppressed over the right base. Râles of all varieties were present in the lower posterior and axillary aspect of the chest, though less numerous over the right base than the left. They were increased by cough. There were numerous coarse, dry, "squeaking" sounds over the upper lobes as well.

The heart was normal in size and position; the sounds were good. There were no murmurs. The pulmonic second sound was accentuated. The systolic blood pressure was 100, diastolic 60. The superficial vessels were thickened and tortuous.

The abdomen, muscles, bones, joints, extremities and nervous sys-

tem present
previously
X-ray
who report
a general
There is g
by pleura
areas thro
"Impi
right bas
some irri

T
No tu
Asbe
pus.
mal.
cent
mor
(Da
neu

effi
pu
ok

tem presented no abnormalities except for the clubbing of the fingers previously noted.

X-ray examination of the chest was made by Dr. Hillyer Rudisill, who reported as follows: "First examination, Jan. 12, 1934: There is a generalized fibrosis throughout both lungs, particularly in the bases. There is generalized increased density in the right base probably caused by pleural thickening. In addition I believe there are bronchiectatic areas through the lower halves of both lungs.

"Impression: Pulmonary fibrosis, pleural thickening (particularly right base), and bronchiectasis, probably the results of inhalation of some irritant material."



FIG. 2. ASBESTO-SILICOSIS WITH CARCINOMA OF LOWER LOBE

The tuberculin (Mantoux), and Wassermann tests were negative. No tubercle bacilli were found in the sputum on numerous examinations. Asbestosis bodies were present in unconcentrated viscid, tough mucus. Tests for fungi were negative. The urinary findings were normal. Blood counts were as follows: Jan. 11, 1934: hemoglobin 80 per cent (Dare), leukocytes 15,525, small and large lymphocytes 11, large mononuclears 3, neutrophils 86; Feb. 20, 1934: hemoglobin 72 per cent (Dare), leukocytes 13,250, small lymphocytes 18, large mononuclears 4, neutrophils 76, eosinophils 2.

The admission diagnosis was pulmonary fibrosis and pleurisy with effusion. The final diagnosis was asbestosis and chronic indurative pneumonia.

Autopsy (R.G.) No. 20514-34-58, March 17, 1934: Summary of pathological diagnoses: Fibrosis of lungs; pulmonary asbestosis; epider-

moid carcinoma of right lung; bronchiectasis; purulent bronchitis; acute pleurisy; chronic myocarditis.

The body is extremely wasted as to adipose tissue and musculature, all muscles, including the interosseous, are quite shrunken. The distal phalanges of the fingers and toes are broad and rounded. The chest is quite prominent anteriorly.

The right lung is densely adherent over its whole surface, but particularly over the lower lobe and at the base, over the diaphragm and toward the spine. The left is adherent rather lightly at the apex and very densely over the lower lobe, particularly over the base and diaphragm. The left pleural cavity over the middle three-fourths con-




FIG. 3. SILICOTIC HYALINE AND CALCAREOUS NODULE IN LUNG, WITH "ASBESTOSIS" BODIES. X 210

tains about 300 c.c. of turbid fluid and there are no attachments here to the outer pleura.

The pleura of the right lung is thickened as a whole and is of cartilaginous and even partly calcareous quality over the base. That of the left lung is likewise thickened, but over the free portion it is rough, congested and "furred," with small nodules in the surface.

The apex of the left lung is composed of a globular mass of light balloon-like emphysematous bullae with intervening fibrous trabeculae, and sub-apically there is a group of small caseous and calcareous hard nodules. The midportion of this lung is light, spongy, dry, and of a mottled dark slaty bluish-gray color. Beginning at the apposition of the interlobar pleura, the lower part of the lung is densely tough, with gross fibrous trabeculation fusing with the thickened pleura, and at the base honeycombed by rounded cavities about the size of bird shot.

The rig
and in the
lung is of
lower asp
débris, ru
to the spi
and the s
or less i
"pocking
The h
moderat

FIG.

eder

pal

apl

be

br

ce

st

pl

et

The right lung has a similar group of balloon-like bullae at the apex and in the midportion is similar to its fellow. The lower third of the lung is of nodular, hard, solidified consistence. Occupying the inner lower aspect, at the spine, is a honeycombed cavity containing caseous debris, ruptured in removing the lung because of its dense adherence to the spine. The inner aspect of the cavity is quite rough, nodular, and the surrounding substance lumpy and caseous. This merges more or less into heavy trabeculated fibrous induration and small cavity "pocking," as in the opposite lung.

The lymph nodes at the root of the lungs are not conspicuous, a few moderately enlarged black nodes being found.

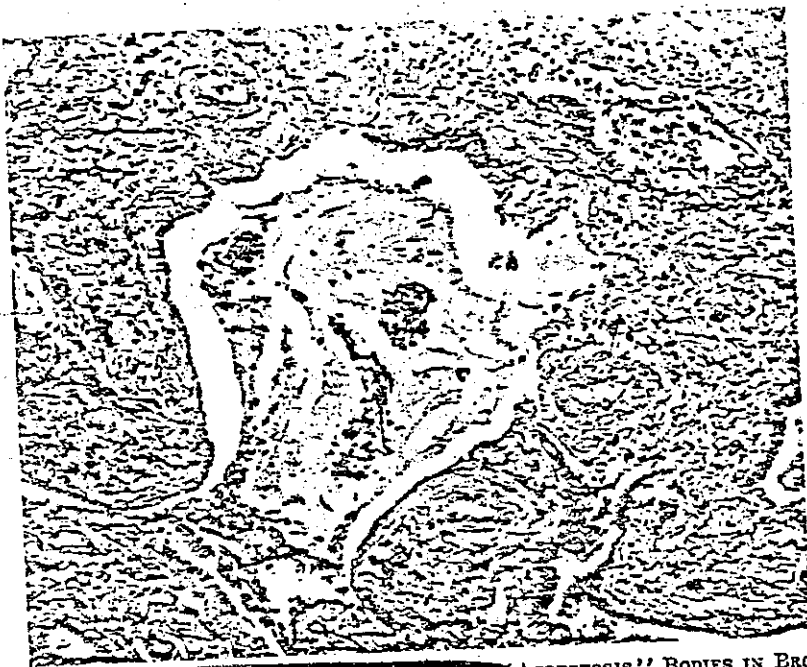

FIG. 4. "ASBESTOSIS" BODIES IN BRONCHIOLE.
X 150

The entire hilar and mediastinal tissue is quite fibrous and edematous.

The heart is not enlarged, but is of rather small size, the muscle pale and flabby, the right cavity moderately dilated.

Other organs and tissues are apparently normal in relations and appearances.

Pathological Diagnoses at Autopsy: Fibrosis of lung; chronic tuberculosis of right lung; chronic fibrous pleurisy; tuberculous pleurisy; bronchiectasis.

Microscopic Findings: Examination of the heart shows quite marked cellular fibrosis of the myocardium, accompanied by some large and small mononuclear cell infiltration. The muscle fibers are hypertrophied and also degenerated. The histologic diagnosis is chronic myocarditis.

In the spleen young fibrous elements and large mononuclear cells increase the thickness of the sinus walls. Polymorphonuclear leukocytes are conspicuous. Here and there are small groups of large "foam" cells, the cytoplasm full of rather large, clear cut vacuoles. In these and other mononuclear cells is a brown granular pigment. A club-shaped asbestosis-like body is seen, whether embedded in the tissue or merely upon it, from transfer from other tissue in cutting, it is difficult to say. The histological diagnosis is chronic splenitis, asbestosis (?).

The kidney is approximately normal, save for congestion.

The liver shows fibrous thickening of the capsule; fibrosis and lymphocytosis of moderate grade in the interlobular framework; patchy

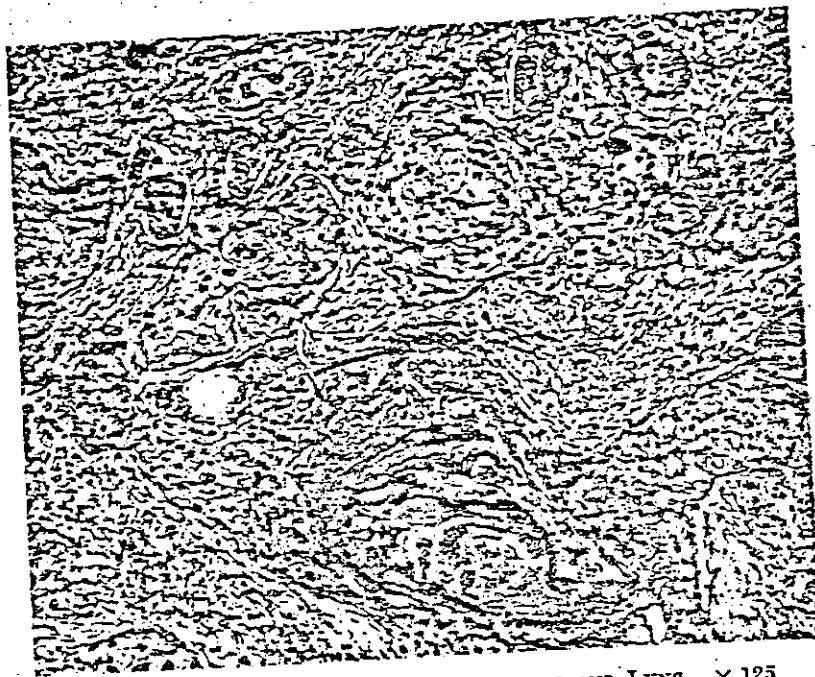


FIG. 5. EPIDERMOID CARCINOMA OF BRONCHUS AND LUNG. $\times 125$

fatty vacuolization of liver cells. Many nuclei of the liver cells are large and cavitated, with a bluish fluid substance within. There are congestion and brown pigmentation of the central venous area. The histological diagnosis is passive congestion, fatty degeneration, portal cirrhosis.

There is chronic fibrous thickening of the pleura, with lymphoid collections, involving both visceral and parietal layers, with an internal covering of leukocytes and fibrin. The histologic diagnosis is chronic fibrous and acute fibrinous pleurisy.

In the peribronchial lymph nodes are heavy deposits of large mononuclear cells containing a black and brownish granular substance in the pulp, with moderate associated fibrosis and deposit of asbestosis bodies, generally of shorter clubbed, rod, and dumb-bell forms. There

is engorgement
clear leukoc
lymphadeniti

In the lu
along the br
generally ok
formation, a

alveoli. Br
there is mu
alveoli are l
jointed, clu

large mono
in the fibro
occur in ly
nuclear or
mucus and

The ple
collections
are seen w
udation of
leukocytos
eral fibro

In the
and empl
empty.

In the
structure
with chro
purulent
of the ov

At th
numbers
spaces
and calc

Sect

culous,
nomato
extensi
theliu

a bron
There

area.
sis tha
tion.

sema,
bronch

s engorgement of the sinuses with serous material and polymorphonuclear leukocytes. The histologic diagnosis is asbestosis and acute lymphadenitis.

In the lung there is comparatively heavy, old interlobular fibrosis, along the bronchi and blood vessels. Broad bands of fibrous tissue, generally old and hyaline, with considerable hyaline laminated nodule formation, are disposed generally in this area, including some adjacent alveoli. Bronchioles here are irregularly and considerably dilated, and there is much deformity of ~~alveoli~~ involved in the fibrosis. In these alveoli are large numbers of asbestosis bodies, generally large, brown, jointed, clubbed, and long dumb-bell shapes, in groups associated with large mononuclear phagocytes. These bodies are also seen embedded in the fibrosed areas, and in some of the bronchioles, while large groups occur in lymph spaces near bronchi. There is only minor small mononuclear or lymphocyte infiltration of the fibrosed tissue, with some mucus and leukocytes in some bronchioles.

The pleura is very thick, composed of old fibrous tissue, and while collections of asbestosis bodies appear in alveoli near the pleura, none are seen within the pleural fibrosed thickening. There is an acute exudation of fibrin upon the pleura, with some hyperemia, edema, and leukocytosis. There is some black granular material in the same general fibrous area.

In the intervening lobules the alveoli are quite deformed by pressure and emphysema, many large air sacs being seen. Generally these are empty.

In the lower left lobe the fibrosis is very heavy, most of the alveolar structure being obliterated, and here there is a marked ~~bronchiectasis~~ with chronic inflammatory infiltration of the walls of the bronchi, some purulent exudate in these bronchi, and active pyogenic inflammation of the overlying thickened pleura.

At the apices there is a remarkable grade of old fibrosis with large numbers of long asbestosis bodies in large giant cells in thick-walled spaces and in fibrosed areas, with hyaline nodule formation, necrosis and calcification, emphysema and bronchiectasis.

Sections from the base of the right lung, thought grossly to be tuberculous, ~~show the caseous cavitation and infiltration that is characteristic of tuberculosis.~~ On a background of heavy fibrosis and bronchiectasis is extensive infiltration by masses and cords of stratified squamous epithelium, maturing in considerable degree. This is shown to come from a bronchus where there is squamous metaplasia of epithelial lining. There are considerable necrosis and purulent leukocytosis of the cavity area. Within and about the carcinoma area there is more active fibrosis than in other portions of the lung, and heavy lymphocytic infiltration. The histologic diagnosis is asbesto-silicosis, with fibrosis, emphysema, bronchiectasis, chronic fibrous and acute pleurisy; ~~epidermoid bronchial carcinoma.~~

SUMMARY

This man had suffered long occupational exposure to dust, some forty-three years all told, about twenty-two in a cotton mill, about twenty-one in an asbestos factory, with resulting fibrosis of extensive grade in the lungs and pleura, the apparent consequences being pulmonary circulatory and respiratory disability, with emphysema, bronchiectasis, and cardiac embarrassment.

As has been observed by us in other cases of asbestosis, one of which has been previously reported (6), the fibrosis of the lungs here bears the accepted characteristic mark of silicosis, that is, in addition to diffused fibrosis, there occurred the formation of hyaline fibrous nodules.

The pulmonary carcinoma appeared to originate from one of the branches of the bronchus to the right lower lobe, where squamous metaplasia of lining epithelium was observed.

The duration of the carcinoma cannot be specified. It was apparently of considerable time but certainly did not antedate fibrosis of the lung. A conception of its origin by reason of chronic bronchial irritation is compatible with the current view of the etiology of such tumors.

REFERENCES

1. PIRCHAN, A., AND SIKL, H.: Cancer of the lung in the miners of Jáchymov (Joachimstal): Report of cases observed in 1929-30, *Am. J. Cancer* 16: 681, 1932.
2. ROSTOSKI, SAUPE, AND SCHMORL: Die Bergkrankheit der Erzbergleute in Schneeberg in Sachsen ("Schneeberger Lungenkrebs"), *Ztschr. f. Krebsforsch.* 23: 360, 1926.
3. SIMPSON, S. L.: Primary carcinoma of the lung, *Quart. J. Med.* 22: 413, 1929.
4. SCHULTE, G.: Pneumconiosen der Ruhrbergleute und Lungenkarzinom, *Fortschr. a. d. Geb. d. Roentgenstrahlen* 41: 444, 1930.
5. SAUPE, E.: Carcinoma of the lung in arsenic miners: two cases, *Arch. f. Gewerbepath. u. Gewerbehyg.* 1: 582, 1930.
6. LYNCH, K. M., AND SMITH, W. A.: Pulmonary asbestosis II, including the report of a pure case, *Am. Rev. Tuberc.* 23: 643, 1931.

LYMPHOS

(From the 1

Lymphos
dition, accor
to report th

The patie
her admission
in the right si
of breath for
appetite ther
nothing of si

The pat
were equal,
ocular move
were negati
The tongue
were not es
hard. The
brownish p
No other a
what enlarg

The :
veins of th
The liver
firm mass
of the u
quadrant
mass whi
movable

The
tion, or
equal ar

The
negative
red blo

Th
The di
lenkoc

O
they v
perfor
mesen
of bl